

# The "Pinch and Slide" Blepharoplasty

## *Safe and Predictable Aesthetic Results*

Marc S. Zimble, MD; Steve Prendiville, MD; J. Regan Thomas, MD

**B**lepharoplasty is one of the most common facial cosmetic surgical procedures. When done properly, this relatively simple operation can result in a dramatic improvement for the patient with relatively little downtime. However, when it is performed improperly, the results can be crippling for the patient and often difficult for the surgeon to correct. Standard treatments for upper eyelid dermatochalasis include surgical excision of skin, muscle, and fat. Several techniques have been described for removing some or all of these components, depending on the patients' anatomic requirements. In particular, the "pinch" technique can be used to remove either the upper eyelid skin alone or a combination of skin, muscle, and fat. While this technique is not new, its appearance in the literature is sparse. We demonstrate herein how a modified version of the pinch technique can be used to remove the central orbital fat pad by "sliding" the pad through the medial fat pad incision. This procedure maintains the integrity of the central orbital septum and the delicate structures that lie beneath.

Arch Facial Plast Surg. 2004;6:348-350

The purpose of this article is not to describe an original concept but rather to further demonstrate the usefulness and versatility of the blepharoplasty "pinch" technique.<sup>1</sup> Furthermore, we detail a refinement that achieves improved and predictable aesthetic results while decreasing the chance for postoperative morbidity. We believe the combination of these 2 techniques adds to the simplicity and safety of the procedure. Moreover, this approach affords the novice surgeon excellent control and can be used as a safe and reliable method for teaching surgical residents.

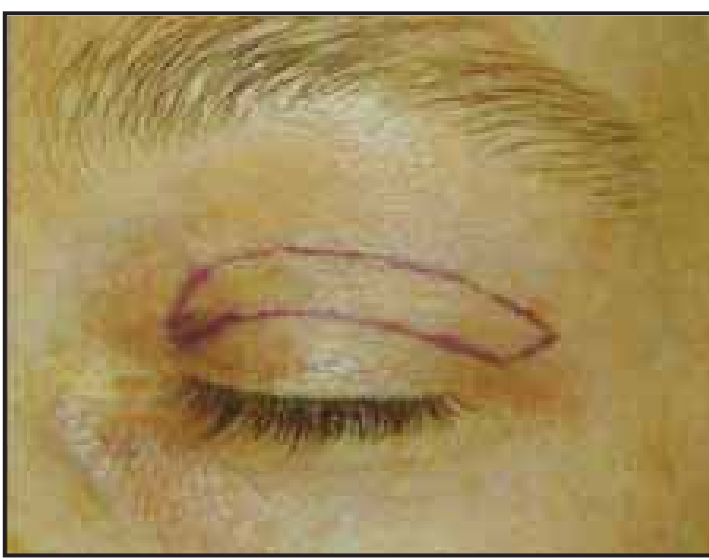### SURGICAL TECHNIQUE

The face is cleaned with a mild cleanser, and the upper eyelid incisions are marked while the patient is in the upright position (**Figure 1**). Thirty milliliters of 1% lidocaine with 1:100000 epinephrine is mixed with 150 U of hyaluronidase. Using a 30-gauge needle, the


surgeon or assistant injects approximately 2 to 4 mL of anesthetic solution, beginning laterally and allowing subdermal infiltration toward the medial canthus. At this point the surgeon scrubs, and the nurse prepares and drapes the patient, allowing approximately 10 minutes to lapse to ensure adequate vasoconstriction.

The lower edge of the Graefe fixation forceps (**Figure 2**) is placed at the level of the naturally occurring eyelid crease. The forceps are used to estimate the amount of excess eyelid skin to be removed. Once the surgeon is satisfied with the amount of tissue grasped, the forceps are clamped tightly (**Figure 3**). The pinched skin edges will hold together, resulting in an easily demarcated line of resection (**Figure 4**). The amount of excised skin varies with the degree of dermatochalasis, and creation of 1 to 2 mm of lagophthalmos is an end point.

The palpebral fissure of the closed eyelid is observed after the skin has been pinched. If more than 1 to 2 mm of lagophthalmos is seen, the skin edges can simply be pulled apart and the procedure repeated before skin excision is performed.



**Figure 1.** Upper eyelid markings are made with the patient in an upright position

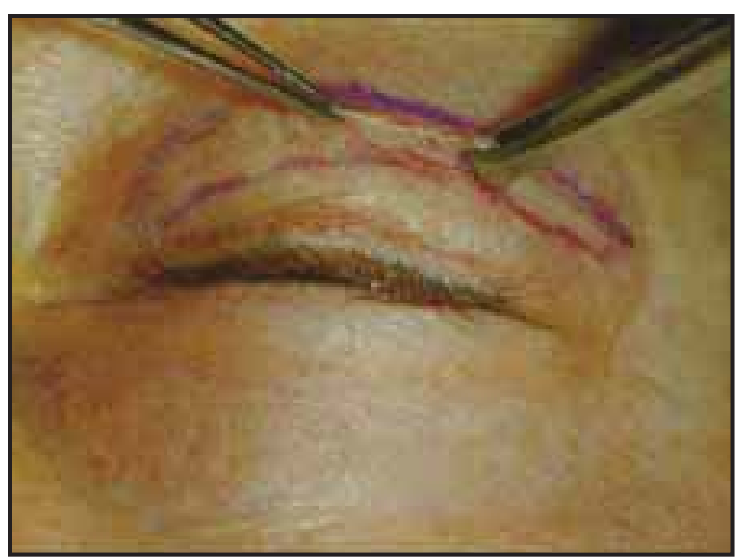

**Figure 2.** Graefe fixation forceps in full-length view (A) and in close-up view of the grasping tips (B).

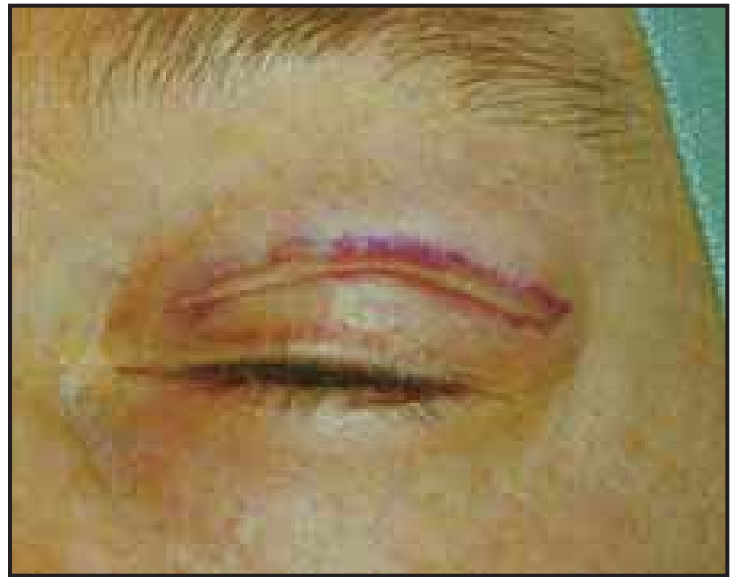The excess skin is then excised, laterally to medially, with sharp serrated scissors as a virtually bloodless maneuver (Figure 5). The skin edges are then separated, and hemostasis is achieved with a disposable ophthalmic cautery.

A strip of orbicularis muscle can be removed at this stage of the procedure. Medial fat pads are removed in a standard fashion through a stab incision in the orbital septum (Figure 6). The central fat pad can be easily visualized and removed through the same stab incision by "sliding" the fat medially (Figure 7). This prevents having to extend the incision over the levator aponeurosis and open the entire orbital septum.

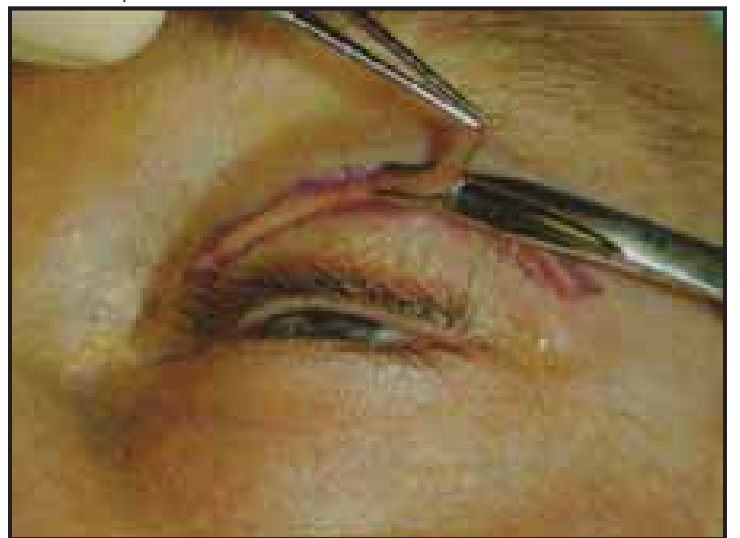After meticulous hemostasis is achieved with bipolar forceps, wound closure is begun. Simple interrupted sutures of 6-0 polypropylene are placed at the lateral orbital rim and medial and lateral limbus to



**Figure 3.** Fine pick-ups assist Graefe fixation forceps in grasping skin.

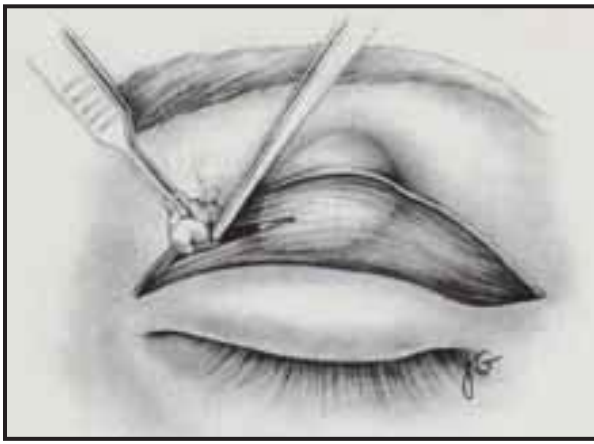


**Figure 4.** The skin edges maintain the "pinched" position after fixation with the Graefe forceps.

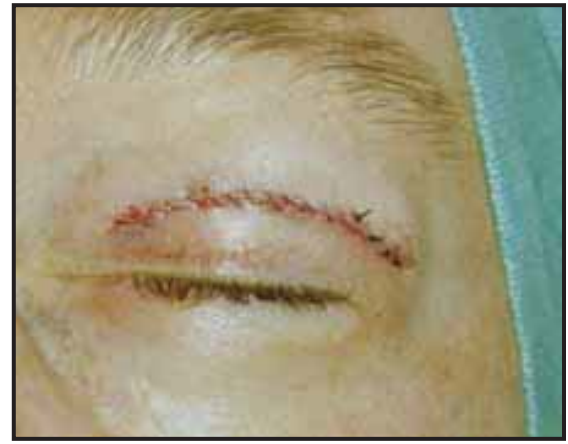

**Figure 5.** Skin pinch excision.

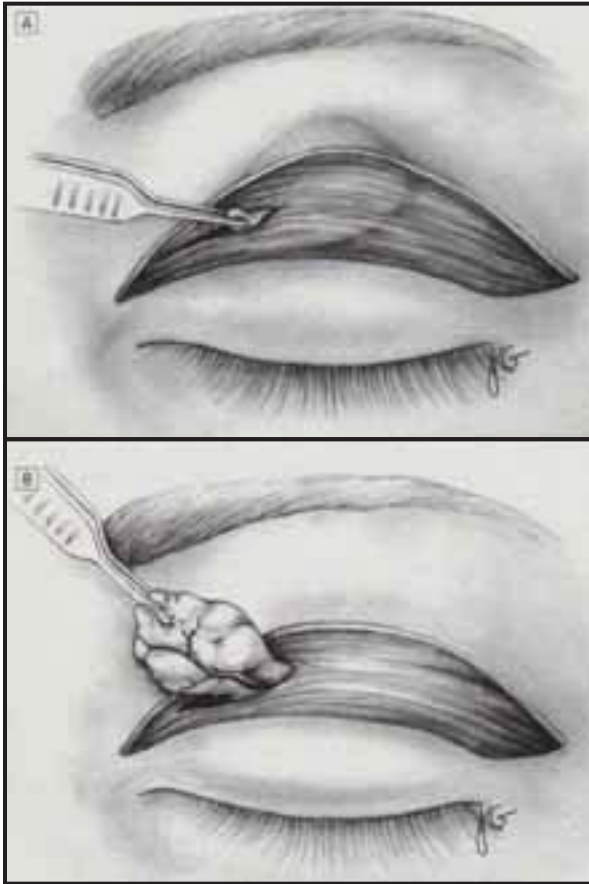
realign the wound edges for closure. Several interrupted sutures are placed in the thicker lateral infrabrow skin where suture tension is greatest. A single running closure is then performed medially to laterally (Figure 8). Cooled ice pads are placed over the eyes for the next 24 to 48 hours, and a combination antibiotic-steroid ointment is placed on the suture line. For the next week. The patient receives a single dose of intravenous



**Figure 6.** Medial fat pad excised in standard fashion.



**Figure 8.** The wound is closed with 6-0 polypropylene suture.



**Figure 7.** A, The central fat pad is grasped through medial stab incision; B, the central fat pad is delivered for standard excision.

antibiotics and steroids and is treated with oral antibiotics for the next 5 days postoperatively.

### COMMENT

The term blepharoplasty was originally coined by von Graefe in 1818 to describe a case of eyelid reconstruction. Since that time, blepharoplasty has become one of the most common cosmetic surgical procedures. While remaining a relatively simple operation, it does carry complications: retrobulbar hematoma, lagophthalmos with exposure keratitis.

For more information visit [www.marczimblermd.com](http://www.marczimblermd.com)

blepharoptosis, and aesthetic asymmetries.<sup>6</sup> For this reason, for the novice surgeon blepharoplasty is a procedure that should not be taken lightly. Moreover the challenging nature of teaching soft-tissue techniques in a surgical residency program does not require explanation.

Herein, we present a technique that is simple to learn and carries a lowered risk of morbidity. With the pinch technique, skin excision is deferred until the exact amount of tissue removal is visualized. This provides a check point that reduces the chances of asymmetry or overresection of tissue. Likewise, central orbital fat removal using the slide technique minimizes potential injury to the delicate central orbital structures.

The fact that a part of this technique is not an original concept deserves reiteration. However, the combination provides a useful and effective means of treating dermatochalasis and orbital fat pseudoherniation. We favor the pinch and slide technique because of its predictable aesthetic results and decreased chance of postoperative morbidity.

*Accepted for publication April 15, 2004.*

*We offer our special thanks to Jill K. Gregory, MFA, for the beautiful illustrations.*

**Correspondence:** Marc S. Zimbler, MD, Department of Otolaryngology—Head and Neck Surgery, Beth Israel Medical Center, 10 Union Sq E, Suite 4J, New York, NY ([mzimbler@bethisraelny.org](mailto:mzimbler@bethisraelny.org)).

### REFERENCES

1. Feldstein M. Skin muscle flap technique in blepharoplasty with use of special clamps. In: Proceedings, First International Symposium on Plastic and Reconstructive Surgery of the Face and Neck. New York, NY: Grune & Stratton; 1970: 66-68.
2. Parkes M, Fein W, Brennan HG. Pinch technique for repair of cosmetic eyelid deformities. *Arch Ophthalmol.* 1973;89:324-328.
3. Thomas JR, Davis DE. Pinch-technique blepharoplasty for the upper eyelid. *Ear Nose Throat J.* 1977;56:367-368.
4. Tardy ME, Thomas JR. *Facial Aesthetic Surgery.* St Louis, Mo: Mosby; 1995: 249-257.
5. von Graefe CF. *De Rhinoplastice.* Berlin, Germany: Reime; 1818:13.
6. Adamson PA, Constantinides MS. Complications of blepharoplasty. *Facial Plast Surg Clin.* 1995;3:2:211-221.